



## ARTICLE

# New left ventricular thrombus and embolic events in left ventricular dysfunction post-myocardial infarction

Ali A. Youssef,<sup>1,2</sup> Shaima Al-Omani,<sup>1</sup> Mustafa A. Alrefae,<sup>1</sup> Ahmad Suliman,<sup>1</sup> Reem Hassan,<sup>1</sup> Omar Saleh,<sup>2</sup> Zizi S. Khalifa<sup>3</sup>

<sup>1</sup>Saud Albabtain Cardiac Center, Dammam, Saudi Arabia; <sup>2</sup>Department of Cardiology, Suez Canal University, Ismailia, Egypt; <sup>3</sup>Department of Cardiology, Zagazig University, Egypt

## Abstract

**Background:** We aimed to assess the incidence and evolution of new left ventricular thrombus (LVT), and the incidence of manifest systemic embolism, in patients with severe left ventricular (LV) systolic dysfunction post-acute anterior myocardial infarction (MI) who had been discharged on dual antiplatelet therapy.

**Methods:** We prospectively included consecutive patients with post-acute anterior MI and LV ejection fraction (LVEF)  $\leq 35\%$  or apical aneurysms or large infarctions with LVEF  $\leq 40\%$ . Transthoracic echocardiography (TTE) confirmed no LVT before hospital discharge, and a second TTE was performed at 30 days and a third one at 3 months. All TTE studies were prespecified to assess LVT, and the patients were screened for the development of clinically manifest systemic embolisms.

**Results:** Two hundred and two consecutive patients (males 93%; mean age  $55.2 \pm 6.4$  years; mean LVEF  $29.5 \pm 5.0\%$ ) were included. At 30 days (interquartile range: 28-37 days), a new LVT was detected in 12 (5.9%) patients. Oral anticoagulant was added to all patients with LVT, and aspirin was continued in 5 (42.7%) patients for a month. The 3-month TTE showed favorable evolution of LV size, LVEF and apical wall motion score index compared to the baseline. At 3 months, the LVT disappeared in 7 (58.3%) patients and 5 patients still had a mural LVT of smaller size, and none got new LVT. Among the group without LVT, one patient had a stroke, and another had a myocardial infarction and died.

**Conclusions:** In contemporary practice, and using routine TTE, the incidence of new LVT in patients with severe LV dysfunction post-acute anterior MI is low. They have a favorable LVT evolution with minor risk for clinically manifest systemic embolism.

**Key words:** ventricular dysfunction, myocardial infarction, ventricular thrombus, systemic embolism, stroke.

Received: 29 December 2023; Accepted: 3 June 2024.

\*Correspondence to: Ali A. Youssef, Department of Cardiology, Suez Canal University, Ismailia, Egypt. E-mail: draliyoussef@gmail.com

## Introduction

Studies reported a very wide range of left ventricular thrombus (LVT) incidences post-acute myocardial infarction (MI) reflecting different population characteristics, timing, and modality of cardiac imaging.<sup>1-4</sup> In a meta-analysis, the rate of LVT by echocardiography within 90 days after anterior ST-segment elevation MI (STEMI) was 9.1%.<sup>1</sup> Another study reported an incidence of LVT in 26% of patients, within a week post-acute anterior MI and LV systolic dysfunction, using transthoracic echocardiography (TTE).<sup>2</sup> With the modern improvements of STEMI pathways, the use of more potent antiplatelets and more updated guidelines directed medical ther-

apy (GDMT), most of the cited data doesn't reflect the contemporary practice.

Transthoracic echocardiography is the routine examination for screening of LVT.<sup>5</sup> Using cardiac magnetic resonance imaging (CMR) with contrast delayed enhancement (CMR-DE) as a gold standard for LVT detection,<sup>2,5,6</sup> routine echocardiography yielded limited sensitivity and negative predictive value. However, other studies,<sup>3</sup> and when the clinical indication for TTE is to assess for LVT, had reported greatly improved TTE performance, evidenced by over a 2-fold higher sensitivity (60% vs. 26%) and 3-fold higher positive predictive value (75% vs. 21%).<sup>5</sup> The early three months post-acute MI is the high-risk interval for thromboembolic events.<sup>7</sup> The clinical significance

of managing patients without anticoagulation when LVT is missed by routine TTE is unknown,<sup>8</sup> especially with contemporary practice. Moreover, prior TTE studies have yielded conflicting results regarding the clinical risks of LVT, with some reporting that thrombus does,<sup>8,9</sup> and others that thrombus does not,<sup>10,11</sup> increase embolic events risk. Consequently, while some scientific bodies support using prophylactic anticoagulation in patients with severe LV dysfunction post-acute MI,<sup>12,13</sup> the report of the American College of Cardiology Foundation/American Heart Association Task Force on Practice Guidelines stated that *anticoagulant therapy may be considered for patients with STEMI and anterior apical akinesis or dyskinesis, with a level of evidence: C*,<sup>14</sup> and the European Society of Cardiology guidelines do not comment on this issue.<sup>15</sup> In this study, we evaluated the incidence of newly diagnosed LVT, its evolution and clinically manifest embolic events in the first three months post-acute anterior MI, using routine, non-contrast TTE, in a cohort with severe LV dysfunction, large akinetic area or apical aneurysm treated according to the contemporary guidelines without additional anticoagulation to fill this controversial and unmet knowledge gap.

## Materials and Methods

### Study population

This prospective study enrolled consecutive patients within a week post-acute anterior MI according to the standard definition of acute STEMI.<sup>16</sup> All enrolled patients had LVEF  $\leq 35\%$  or  $\leq 40\%$  with a large LV akinetic area (apical wall motion score index  $\geq 2.5$ ) or apical aneurysm. The patients did not have proved or suspected LVT by TTE, did not have any indication for oral anticoagulation, and were in sinus rhythm. Patients staged for coronary revascularization or had systemic embolism within the past 6 months were excluded.

### Study end points

Incidence of newly diagnosed LVT in one month and three months.

Incidence of embolic events in the first three months.

### Endpoints definition

Left ventricular thrombus is an echo-dense mass distinct from the endocardium with well-defined edges adjacent to hypokinetic, akinetic, or aneurysmal myocardial segments and seen in 2 or more views.<sup>2,5</sup>

A stroke was defined as a new-onset focal or global neurologic deficit caused by ischemia, or hemorrhage preceded by infarction, as assessed by appropriate imaging, including computed tomography (CT) or CMR, and lasting for  $>24$  hours or leading to death. A deficit lasting  $<24$  hours was defined as a transient ischemic attack.<sup>17</sup>

Other sites, systemic embolism, were counted with a solid di-

agnosis based on imaging, or best clinical judgement and the treatment as systemic embolism.

Death when cardiac or attributed to systemic embolic event.

### Echocardiography

All patients had a non-contrast TTE study, with a thrombus-specific indication, before discharging post-acute anterior MI, at one month and three months. Experienced and certified sonographers performed the TTE studies. All examinations involved a Vivid E9 (1.5-4.6 MHz gauge; second harmonic imaging; GE Vingmed Ultrasound AS, Horten, Norway) and Philips IE33 (5-1 MHz gauge, S5-1 sector array probe; Philips, Amsterdam, the Netherlands) echocardiography machines. Views were acquired in the standard imaging planes following the American Society of Echocardiography recommendations.<sup>18</sup> Another TTE study was scheduled before discharge if an earlier study showed suspicion or a higher risk of developing LVT. Images were interpreted by consensus of two independent, experienced readers (Level III trained in echocardiography). A pre-designated third reader was consulted in cases of interpretive discordance. Thrombus morphology was classified as protuberant (protrusion into LV cavity) or mural (borders were contiguous and parallel with adjacent endocardial contours);<sup>19</sup> thrombus volume was measured via planimetry and lengths. The Simpson method measured the left ventricular volumes and ejection fraction. Also, the wall motion score index (WMSI) of the 4-apical segments was calculated.<sup>5</sup>

### Intervention, medical therapy, and follow-up

All patients were treated according to the standards of acute anterior myocardial infarction management;<sup>15</sup> including reperfusion with primary percutaneous coronary intervention (PCI) or lytic therapy followed by PCI. Parenteral anticoagulation with heparin continued until culprit vessel revascularization or TTE confirmed no LVT, whatever occurred later, and all patients were discharged on GDMT including dual antiplatelets. All patients had a clinical assessment at the one-month and three-month follow-up. Also, the patients and their caring relatives were in contact for any emergency department visits or hospital admissions.

Patients' clinical information was obtained via: i) prospective direct assessment and hospital records, ii) telephone interviews with the patient and/or family members and iii) contact with the patient's physician.

For patients with an incident LVT, an oral anticoagulant was advised for 3-6 months, in addition to antiplatelet therapy. The use of triple therapy applied the best evidence and guidelines.<sup>14,15,20,21</sup>

### Statistical analysis

Given the incidence of LVT (19.2% in acute anterior MI with LVEF  $<50\%$ ) using CMR-DE in a similar population,<sup>3</sup> and 7% at 1-7 days after MI with LVEF  $<40\%$  using routine TTE,<sup>5</sup> and reason-

able sensitivity of thrombus specific-TTE study in detecting LVT compared to CMR-DE,<sup>2,3,5</sup> we estimated a sample size of 200 patients, including 10% dropouts. Data are reported as mean  $\pm$  SD or median with interquartile range (IQR, 25-75%) for continuous variables and n (%) for categorical variables. Unpaired Student t-test and Fisher exact test were used to compare differences between continuous and categorical variables, respectively.  $p < 0.05$  was considered statistically significant.

## Results

Between March 15, 2018, and February 22, 2023, all consecutive patients with acute anterior wall ST-segment elevation myocardial infarction were screened during hospitalization, and 211 patients were eligible (Figure 1). Nine enrolled patients missed the 1-month follow-up, with no clinical adverse events for 4 of them based on telephone calls. Additional 10 (non-citizens) lost the 3-month follow-up and can't be contacted (of them 4 patients had the scheduled TTE study), and one patient died after 2 months of enrolment. Therefore, 202 (+4 via telephone call) and 191 (+4 echocardiography data) patients had complete data at 1 month and 3 months, respectively, and were included in the analysis.

### Baseline demographic, laboratory, and angiographic data

The mean age of the study enrollees was  $53.3 \pm 8.8$  years, including 93.1% males, and 103 (51%) as non-Saudi citizens. At 1 month, 12 patients (5.94%, out of the 202 patients) had a new LVT. The patients with LVT were older, all males, more non-citizens (66.7%) and had more total and LDL cholesterol (Table 1).

For the patients with a 1-month follow-up, 52% had a late presentation to a medical facility (beyond 12 hours from chest pain

onset), including 49 patients (24.25%) who presented beyond 24 hours and underwent PCI. Also, 197 (97.52%) had acute anterior wall MI, and 5 patients had non-anterior wall MI, as proved by coronary angiography later. Also, 28 (13.9%) patients had a history of coronary artery disease (CAD), and 13 (6.43%) patients were known before to have CAD with low LVEF (<40%). All patients with 1-month follow-up underwent coronary angiography and stenting. Coronary angiography revealed 2-3 vessels CAD in 118 (58.4%), and coronary stenting was performed in a single vessel in 145 (71.78%) and in two or more vessels in 57 (28.2%) patients. The left anterior descending coronary artery (LAD) was the culprit in 195 (96.53%) patients.

### Incidence of left ventricular thrombus at 1-month follow-up

The baseline echocardiography showed a mean LVEF of  $30.2 \pm 5.0\%$ , the apical WMSI was  $2.75 \pm 0.3$ , and 64 patients (31.7%) had a picture of early LV aneurysm (Table 2). Twelve patients (5.94%) had LVT that was discovered at the 1-month visit with a median of 33 days (IQR 28-37 days) after MI. The LVT was more in late-presented patients, and all had anterior wall MI. Eleven LVT cases were confirmed by the two independent echocardiographers with high confidence. Contrast echocardiography was done for 5 cases with suspicious LVT, and only one case had a confirmed LVT.

### Anticoagulation and other medical treatment

All patients discharged on DAPT; aspirin (81 mg/day) in all, and either ticagrelor (174 patients), or clopidogrel (28 patients) (Table 3). Heparin (unfractionated or low molecular weight heparin) was used in 175 (86.6%) during the index admission till echocardiography ruled out LVT. The patients who later developed LVT had a longer duration of heparin use. Also, tirofiban was used in 107 (53%) patients including 7 (58.3%) patients who later developed LVT.

Among the patients with LVT, 3 were on DAPT including clopidogrel, and 9 were on DAPT including ticagrelor when the LVT was discovered at 1 month. All patients on ticagrelor were shifted to clopidogrel, and warfarin was added in 5 patients and apixaban (5 mg twice daily) in 7 patients with LVT. Aspirin was discontinued in 3 of the LVT patients who started on warfarin and 4 patients who started on apixaban. Two new patients without LVT were found to have new atrial fibrillation at 1 month and were started on apixaban (5 mg twice daily). Otherwise, the GDMT was well achieved in the study population (Table 3).

### Study clinical events

The LVT patients had a longer baseline hospital stay ( $4.3 \pm 3.4$  vs.  $2.2 \pm 1.55$  days). However, none of them developed adverse clinical events during the study. Among the no-LVT group; one patient died after 2 months with a new culprit MI, cardiogenic shock, and sepsis. Another patient had a stroke, likely embolic, during the first month of follow-up.

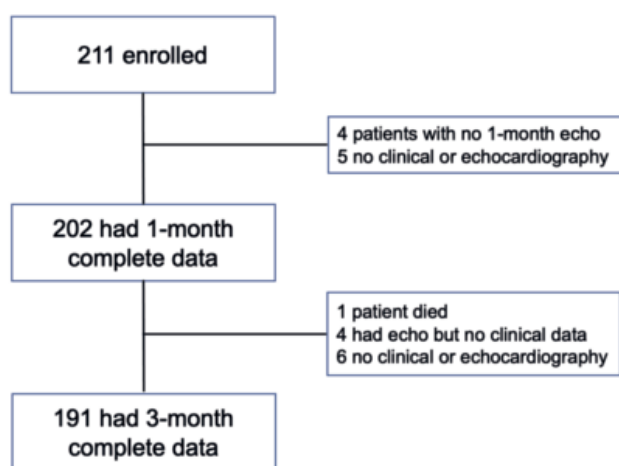


Figure 1. Patients enrolled in the study.

**Table 1.** Comparison of the demographics of patients with left ventricular thrombus versus no left ventricular thrombus.

	Thrombus (n=12)	No thrombus (n=190)	p
Male	12(100)	176 (92.6)	0.333
Age (mean±SD)	58±3.3	52±8.9	0.032
Nationality			
Citizen	4 (33.3)	95 (50)	0.263
Non-citizen	8 (66.7)	95 (50)	
Smoking			
Never	7 (58.3)	72 (38)	0.159
Current or former	5 (41.7)	118 (62)	
HTN	8 (66.7)	94 (49.5)	0.248
DM	8 (66.7)	102 (53.7)	0.381
Dyslipidaemia	4 (33.3)	50 (26.3)	0.458
History of old MI	3 (25)	21 (11.1)	0.148
Previous PCI	3 (25)	21 (11.1)	0.148
History of low EF	2 (16.7)	11 (5.8)	0.136
MI to PCI			0.047
Within 24 hrs	7 (58.3)	146 (76.8)	
Over 24 hrs	5 (41.7)	44 (23.2)	
Late presentation*	8 (66.7)	143 (75.3)	0.193
Anterior MI	12 (100)	185 (97.4)	0.569
Serum creatinine	1.24±0.29	1.14±0.58	0.574
Total cholesterol	226±43.3	186±47.2	0.009
LDL	176.6±21.3	121.6±42.7	<0.001
No. of diseased vessels			
One	6 (50)	78 (41.1)	
Two	2 (16.7)	56 (29.5)	0.632
Multivessel	4 (33.3)	56 (29.5)	
No. of treated vessels			
One	8 (66.7)	137 (72.1)	
Two	4 (33.3)	50 (26.3)	0.801
Three	0	3 (1.6)	
Primary PCI**	7 (58.3)	143 (75.3)	0.193
Post PCI TIMI III flow	10 (83.3)	186 (97.8)	0.004

SD, standard deviation; HTN, hypertension; DM, diabetes mellitus; MI, myocardial infarction; PCI, percutaneous coronary intervention; TIMI, thrombolysis in myocardial infarction. \*Late presentation is beyond 12 hours of the typical chest pain onset. \*\*PCI in the first 24 hours from myocardial infarction onset unpreceded using a lytic.

**Table 2.** Echocardiographic data and clinical outcome of with left ventricular thrombus versus no left ventricular thrombus.

	Thrombus (n=12)	No thrombus (n=190)	p
Hospital stay (mean±SD)	4.3±3.4	2.2±1.55	<0.001
Hospital stay			
<3 days	4 (33.3)	119 (62.6)	
3-7 days	7 (58.3)	67 (35.3)	0.042
>7 days	1 (8.3)	4 (2.1)	
Duration to echo			
Within 48 hours	10 (83.3)	162 (85.3)	0.855
After 48 hours	2 (16.7)	28 (14.7)	
Dilated LV	12 (100)	170 (89.5)	0.236
Aneurysm	4 (33.3)	60 (31.6)	0.899
EF at baseline (Mean±SD)	28.3±4.9	30±5	0.179
EF after 1 month (Mean±SD)	28.2±6	33.7±7.4	0.011
EF after 3 months (Mean±SD)	26.8±2.2	36±7.4	0.003
Apical WMSI at baseline	2.8±0.26	2.7±0.33	0.510
Apical WMSI after 1 month	2.96±0.41	2.41±0.56	0.001
Apical WMSI after 3 months	3.0±0.35	2.3±0.59	0.008
Death	0	1	0.796
Stroke	0	1	0.801
Recurrent MI	0	1	0.801
Bleeding*	0	3	0.651

SD, standard deviation; LV, left ventricle; EF, ejection fraction; WMSI, wall motion score index; MI, myocardial infarction. \*Bleeding was minor in 2 patients and needed admission in the 3<sup>rd</sup> (gastrointestinal bleeding, melena).

**Table 3.** Medication use in the study groups.

Variable	Thrombus (n=12)	Non thrombus (n=190)	p
Medication used in the study groups on discharge			
Thrombolytic	5 (41.7)	42 (22.1)	0.012
Tirofiban	7 (58.3)	100 (52.6)	0.701
DAPT use	12 (100)	190 (100)	0.801
Clopidogrel	3 (25)	25 (13.2)	0.250
Ticagrelor	9 (75)	165 (86.8)	0.071
Beta-blocker	11 (91.7)	184 (96.8)	0.342
ACEi/ARB	12 (100)	177 (93.2)	0.349
Spironolactone	7 (58.3)	149 (78.4)	0.108
Loop diuretics	8 (66.7)	89 (46.8)	0.182
Statins	12 (100)	190 (100)	0.362
Medications used in the study groups after the first month			
DAPT use	5 (42.7)	189 (99.5)	0.801
Clopidogrel	12 (100)	27 (14.2)	0.250
Ticagrelor	0	163 (85.8)	0.071
OAC			
None	0	188 (98.9)	
Warfarin	5 (42.7)	0	<0.0001
Apixaban	7 (57.3)	2 (1.1)	
Beta-blocker	11 (91.7)	184 (96.8)	0.342
ACEi/ARB	12 (100)	177 (93.2)	0.349
Spironolactone	7 (57.3)	149 (78.4)	0.108
Loop diuretics	8 (66.7)	89 (46.8)	0.182
Statins	12 (100)	190 (100)	0.362

DAPT, dual antiplatelet therapy; ACEi, angiotensin converting enzyme inhibitor; ARB, angiotensin receptor blocker; OAC, oral anticoagulants.

Recurrent MI occurred in an additional patient who got a large groin hematoma. Two more patients got more than 3 grams of hemoglobin drop, with stool color changes suggesting gastrointestinal bleeding, and were treated conservatively. Two patients developed new-onset atrial fibrillation diagnosed at 1 month follow-up and aspirin was replaced with apixaban. All these patients had no echocardiographic evidence of LVT (Table 2).

### Left ventricular remodeling and left ventricular thrombus evolution at 3-month follow-up

The 3-month echocardiography (Table 4) showed favorable LV remodeling compared to the baseline. The cases with enlarged LV were 140 (71.8%) vs. 182 (90.1%), ( $p < 0.001$ ), the LVEF improved ( $35.7 \pm 7.6$  vs.  $30.2 \pm 5.03$ ,  $p < 0.001$ ) and the apical WMSI improved ( $2.32 \pm 0.59$  vs.  $2.75 \pm 0.3$ ,  $p < 0.001$ ). Importantly, there was a resolution of LVT in 7 out of the 12 cases (58.3%). All remaining LV thrombi were of smaller size and mural, and no new LVT emerged in the interval of 1 to 3 months.

## Discussion

### Low incidence of left ventricular thrombus in the contemporary era

Our study revealed a low incidence (5.94%) of LVT, even in patients with severe LV dysfunction post-acute anterior MI. One post-PCI era study reported LVT in 9.1% of those with anterior STEMI,<sup>1</sup> and Meurin *et al.*<sup>2</sup> reported an incidence of 26% in a

similar population using TTE. The standard routine imaging modality for screening and follow-up of LVT post-MI is echocardiography. The thrombus-specific TTE sensitivity is reasonably high,<sup>5,22</sup> and was safely applied in our study. Also, we didn't report new LVT beyond one month, and the LV thrombi persisted, under treatment, from 1 to 3 months had a lower risk of embolization. In a recent publication, using CMR, the incidence of LVT post-STEMI and depressed LVEF was almost triple that in our study.<sup>3</sup> On the one hand, the missing of LVT in our study should be small, and on the other hand, most potential echocardiography-missed LV thrombi are typically small, and mural with a lower risk of embolization.<sup>5</sup> The management standards of acute MI, including coronary revascularization, potent DAPT and GDMT, and recovery from myocardial stunning are associated with a low incidence of new LVT formation, including the highest-risk post-acute anterior MI population with a large infarction area.<sup>2,19,22</sup> Adopting TTE as a surveillance and follow-up imaging modality for LVT post-acute MI is reasonable, and most reassuring when thrombus-specific protocols are applied as we confirmed.

### Modern dual antiplatelet therapy and guidelines directed medical therapy potentially prevent and ameliorate left ventricular thrombus risk

Our study showed a single case of stroke, without confirming LVT, and no new LVT between 1- and 3-months TEE follow-up. Based on meta-analyses, prophylactic anticoagulation among patients with STEMI and anterior apical akinesis or dyskinesis

**Table 4.** Evolution of echocardiographic parameters and clinical outcome in the study population

Echo	Baseline (n=211)	One month (n=202)	Three months*	p
	No (%)	No. (%)	No. (%)	
Dilated LV size	182 (90.1)	154 (76.2)	140 (71.8)	0.001
MR				
No MR	173 (85.6)	165 (81.7)	157 (80.5)	
Mild	26 (12.9)	21 (10.4)	23 (11.8)	
Moderate	2 (1)	13 (6.4)	12 (6.2)	0.0204
Severe	1 (0.5)	3 (1.5)	3 (1.5)	
Apical aneurysm	64 (31.7)	79 (39.1)	81 (41.5)	0.071
WMSI (mean ±SD)	2.75±0.3	2.44±0.56	2.32±0.59	0.001
EF (mean±SD)	30.2±5.03	33.4±7.38	35.7±7.6	0.001
Thrombus	0	12 (5.9)	5 (2.56)	0.358
Thrombus shape				
Mural	0	8/12 (66.7)	5 (100)	0.331
Protruding	0	4/12 (33.3)	0 (0)	
Thrombus mobility				
Immobile		8/12 (66.7)	5/5 (100)	0.331
Mobile		4/12 (33.3)	0 (0)	
Thrombus length	-	6.5±6.58	3.8±2.47	0.032
Thrombus width	-	3.5±3.61	0.59±0.2	0.022
Thrombus area	-	1.9±2.2	0.75±0.39	0.011
Stroke	-	1 (0.5)	0 (0)	0.413
Systemic embolism <sup>o</sup>	-	0 (0)	0 (0)	-
Recurrent MI	-	1 (0.5)	2 (1.0)	0.345
Death	-	0 (0)	1 (0.5)	0.221
Bleeding <sup>#</sup>	-	0 (0)	3 (1.6)	0.033

LV, left ventricular; MR, mitral regurgitation; WMSI, wall motion score index; EF, ejection fraction; SD, standard deviation; MI, myocardial infarction.

\*Echo data of 195; clinical data of 191. <sup>o</sup>Systemic embolism other than stroke. <sup>#</sup>Bleeding was minor in 2 patients and needed admission in the third (gastric bleeding, melena).

at risk for LVT may be considered (class IIb), with a level of evidence C, in the 2013 ACC/AHA STEMI guidelines.<sup>14</sup> There is a potential impact of the potent DAPT and the use of GDMT on the prevention and resolution of LVT,<sup>23,24</sup> and the addition of oral anticoagulation to DAPT to prevent LVT among patients with anterior MI did not reduce the adverse events,<sup>25,26</sup> and potentially increased major bleeding.<sup>25-27</sup> The development of LVT in the modern era of management appears to have a relatively benign course, irrespective of anti-thrombotic therapy.<sup>28,29</sup> None of the patients with documented LVT post-acute anterior MI had evidence of stroke when DAPT was compared to triple therapy.<sup>26</sup> Prophylactic warfarin use in patients with acute MI and large areas of akinesis or dyskinesis showed no reduction of embolic risk but significant bleeding risk.<sup>25,27</sup> Given the benefit *versus* risk, the current evidence and our findings do not support prophylactic anticoagulation in the contemporary era, even in a similar high-risk population.

### The benign evolutionary course of left ventricular thrombus and left ventricular remodeling with contemporary practice

The risk of LVT formation after acute MI may be greatest in the first 2 weeks.<sup>30,31</sup> We could have missed diagnosing LVT without TTE surveillance at this time. However, we had only one patient who got a stroke (0.49%), without evidence of LVT on TEE, and

another who died after complications of recurrent MI. Studies showed that the risk predictors of systemic embolization with LVT were thrombus mobility and protrusion, while the severity of LV systolic dysfunction and the presence of mural thrombus did not impact this event.<sup>2,22,31</sup> In our study, the LVT detected at one month included protruding and mobile thrombi, but at 3 months a bigger number of the thrombi had resolved, and the remaining were all smaller and mural. So, LVT nature had been changed from higher to lower embolization risk, probably as the more mobile parts are softer or less organized, with more surface area exposed and responding to the anticoagulant/anti-thrombotic action of the medications and natural auto-anticoagulation. Additionally, over 3 months of follow-up, there was a regression of LV dilation, improvement of LVEF and apical WMSI, regression of LVT size and risk characteristics and lack of emergence of new LVT. The reverse remodeling potentially reverses the mechanisms of LVT formation. These findings add to the proof against the use of prophylactic anticoagulation in this population and should reassure the concerned medical societies to disregard randomization.

### Conclusions

With contemporary practice and using TTE, our study showed a low incidence of LVT in patients with post-acute anterior MI,

with severe LV dysfunction and a large area of akinesis or dyskinesia. The study showed favorable LV remodeling and LVT evolutionary changes, with a very low risk of manifest systemic embolization.

## Acknowledgements

The authors appreciate the research coordinators, Layla Al-houty and Josephine-Grace Chua, for their efforts in this work.

## Contributions

Study idea, conduct, data analysis and writing the final manuscript (Ali A. Youssef, Shaima Al-Omani and Zizi Saad). Interpreting and performing the echocardiographic studies (Mustafa A. Alrefae, Ahmad Suliman and Reem Hassan). Statistical analysis and interpretation (Omar Saleh and Ali A. Youssef). All the authors have reviewed and approved this manuscript.

## Conflict of interest

The authors declare no potential conflict of interest.

## Ethical approval

The study has been approved by the local ethics committee of Saud AlBabtain Cardiac Centre, Dammam, Saudi Arabia, (IRB-2018-11), and has been performed following the ethical standards of the 1964 Declaration of Helsinki and its later amendments. All persons gave their informed consents before their inclusion in the study, and the consent included their acceptance of publications of the acquired data.

## References

- Robinson AA, Jain A, Gentry M, McNamara RL. Left ventricular thrombi after STEMI in the primary PCI era: A systematic review and meta-analysis. *Int J Cardiol* 2016;221:554-9.
- Meurin P, Brandao Carreira V, Dumaine R, et al. Incidence, diagnostic methods, and evolution of left ventricular thrombus in patients with anterior myocardial infarction and low left ventricular ejection fraction: a prospective multicenter study. *Am Heart J* 2015;170:256-62.
- Bulluck H, Chan MHH, Paradies V, et al. Incidence and predictors of left ventricular thrombus by cardiovascular magnetic resonance in acute ST-segment elevation myocardial infarction treated by primary percutaneous coronary intervention: a meta-analysis. *J Cardiovasc Magn Reson* 2018;20:72.
- Saric M, Armour AC, Arnaout MS, et al. Guidelines for the use of echocardiography in the evaluation of a cardiac source of embolism. *J Am Soc Echocardiogr* 2016;29:1-42.
- Weinsaft JW, Kim HW, Crowley AL, et al. LV thrombus detection by routine echocardiography. *J Am Coll Cardiol Img* 2011;4:702-12.
- Mollet NR, Dymarkowski S, Volders W, et al. Visualization of ventricular thrombi with contrast-enhanced magnetic resonance imaging in patients with ischemic heart disease. *Circulation* 2002;106:2873-6.
- Witt BJ, Brown RD Jr, Jacobsen SJ, Weston SA, Yawn BP, Roger VL. A community-based study of stroke incidence after myocardial infarction. *Ann Intern Med* 2005;143:785-92.
- Stratton JR, Resnick AD. Increased embolic risk in patients with left ventricular thrombi. *Circulation* 1987;75:1004-11.
- Crawford TC, Smith WT, Velazquez EJ, Taylor SM, Jollis JG, Kisslo J. Prognostic usefulness of left ventricular thrombus by echocardiography in dilated cardiomyopathy in predicting stroke, transient ischemic attack, and death. *Am J Cardiol* 2004;93:500-3.
- Nihoyannopoulos P, Smith GC, Maseri A, Foale RA. The natural history of left ventricular thrombus in myocardial infarction: a rationale in support of masterly inactivity. *J Am Coll Cardiol* 1989;14:903-11.
- Ciaccheri M, Castelli G, Cecchi F, et al. Lack of correlation between intracavitary thrombosis detected by cross sectional echocardiography and systemic emboli in patients with dilated cardiomyopathy. *Br Heart J* 1989;62:26-9.
- Vaitkus PT, Barnathan ES. Embolic potential, prevention and management of mural thrombus complicating anterior myocardial infarction: a meta-analysis. *J Am Coll Cardiol* 1993;22:1004-9.
- Andreotti F, Testa L, Biondi-Zoccai GG, Crea F. Aspirin plus warfarin compared to aspirin alone after acute coronary syndromes: an updated and comprehensive meta-analysis of 25,307 patients. *Eur Heart J* 2006;27:519-26.
- O'Gara PT, Kushner FG, Ascheim DD, et al. ACCF/AHA guideline for the management of ST-elevation myocardial infarction: a report of the American College of Cardiology Foundation/American Heart Association Task Force on Practice Guidelines. *J Am Coll Cardiol* 2013;61:e78-140.
- Ibanez B, James S, Agewall S, et al. ESC Guidelines for the management of acute myocardial infarction in patients presenting with ST-segment elevation: the task force for the management of acute myocardial infarction in patients presenting with ST-segment elevation of the European Society of Cardiology (ESC). *Eur Heart J* 2017;39:119-77.
- Thygesen K, Alpert JS, Jaffe AS, et al. Fourth universal definition of myocardial infarction. *Circulation* 2018;138:e618-51.
- Kleindorfer DO, Towfighi A, Chaturvedi S, et al. Guideline for the prevention of stroke in patients with stroke and transient ischemic attack: a guideline from the American Heart Association/American Stroke Association. *Stroke* 2021;52:e364-467.
- Lang RM, Badano LP, Mor-Avi V, et al. Recommendations for cardiac chamber quantification by echocardiography in adults: an update from the American Society of Echocardiography and the European Association of Cardiovascular Imaging. *J Am Soc Echocardiogr* 2015;28:1-39.
- Domenicucci S, Chiarella F, Bellotti P, Bellone P, Lupi G, Vecchio C. Long-term prospective assessment of left ventricular thrombus in anterior wall acute myocardial infarction and implications for a rational approach to embolic risk. *Am J Cardiol* 1999;83:519-24.
- Zwart B, Bor WL, de Veer AJ, et al. A novel risk score to identify the need for triple antithrombotic therapy in patients with atrial fibrillation undergoing percutaneous coronary intervention: a post hoc analysis of the RE-DUAL PCI trial. *EuroIntervention* 2022;18:e292-302.
- Lip GY, Windecker S, Huber K, et al. Management of antithrombotic therapy in atrial fibrillation patients presenting with acute

- coronary syndrome and/or undergoing percutaneous coronary or valve interventions: a joint consensus document of the European Society of Cardiology Working Group on Thrombosis, European Heart Rhythm Association (EHRA), European Association of Percutaneous Cardiovascular Interventions (EAPCI) and European Association of Acute Cardiac Care (ACCA) endorsed by the Heart Rhythm Society (HRS) and Asia-Pacific Heart Rhythm Society (APHRS). *Eur Heart J* 2014;35:3155-79.
22. Khoury S, Carmon S, Margolis G, Keren G, Shacham Y. Incidence and outcomes of early left ventricular thrombus following ST-elevation myocardial infarction treated with primary percutaneous coronary intervention. *Clin Res Cardiol* 2017;106:695-701.
  23. Altıntaş B, Altındağ R, Bilge Ö, et al. The effect of ticagrelor-based dual antiplatelet therapy on the development of late left ventricular thrombus after acute anterior ST-elevation myocardial infarction. *Int J Cardiol* 2019;287:19-26.
  24. Bastiany A, Matteau A, El-Turaby F, et al. Comparison of systematic ticagrelor-based dual antiplatelet therapy to selective triple antithrombotic therapy for left ventricle dysfunction following anterior STEMI. *Sci Rep* 2018;8:10326.
  25. Shavadia JS, Youngson E, Baine KR, Bakal J, Welsh RC. Outcomes and prognostic impact of prophylactic oral anticoagulation in anterior ST-segment elevation myocardial infarction patients with left ventricular dysfunction. *J Am Heart Assoc* 2017;6:e006054.
  26. Oyetayo OO, Slicker K, De La Rosa L, et al. Dual antiplatelet compared to triple antithrombotic therapy in anterior wall acute myocardial infarction complicated by depressed left ventricular ejection fraction. *Proc (Bayl Univ Med Cent)* 2015;28:445-9.
  27. Moulson N, LaHaye SA, Bertrand OF, MacHaalany J. Prophylactic warfarin post anterior ST-elevation myocardial infarction: a systematic review and meta-analysis. *Cardiovasc Revasc Med* 2017;18:559-64.
  28. Delewi R, Nijveldt R, Hirsch A, Marcu CB, Robbers L, et al. Left ventricular thrombus formation after acute myocardial infarction as assessed by cardiovascular magnetic resonance imaging. *Eur J Radiol* 2012;81:3900-4.
  29. Zhang Z, Si D, Zhang Q, et al. Prophylactic rivaroxaban therapy for left ventricular thrombus after anterior ST-segment elevation myocardial infarction. *JACC Cardiovasc Interv* 2022;15:861-72.
  30. Asinger RW, Mikell FL, Elspeger J, Hodges M. Incidence of left-ventricular thrombosis after acute transmural myocardial infarction. Serial evaluation by two-dimensional echocardiography. *N Engl J Med* 1981;305:297-302.
  31. Küpper AJ, Verheugt FW, Peels CH, Galema TW, Roos JP. Left ventricular thrombus incidence and behavior studied by serial two-dimensional echocardiography in acute anterior myocardial infarction: left ventricular wall motion, systemic embolism and oral anticoagulation. *J Am Coll Cardiol* 1989;13:1514-20.